

## Rare Findings in The Groin Mimicking Hernia in A Woman

<sup>1</sup>Skarpas Andreas, Kondyli Panagiota<sup>1</sup>, Athanasios Zoikas<sup>1</sup>, Georgios Vletsis<sup>2</sup>, Emmanouela Griva<sup>1</sup>, Nikolaos Nikitakis<sup>1</sup>, Ioannis Karanikas<sup>1</sup>, Velimezis Giorgos<sup>1</sup>

<sup>1</sup>Department Sismanoglion G.H Maroussi, Greece,

<sup>2</sup>Department 251 Airforce Hospital Athens, Greece

This is an Open Access article distributed under the terms of the Creative Commons Attribution License (<http://creativecommons.org/licenses/by/4.0>), which permits unrestricted use, distribution, and reproduction in any medium, provided the original work is properly cited.

### ABSTRACT

**Introduction:** Groin hernias have a wide variety of clinical presentations. Diagnosis relies mostly on the patient's history and/or clinical symptoms. Advanced diagnostics are scarcely required.

**Study Design:** There are cases when there is doubt in the diagnosis, imaging can then help differentiate such cases.

**Material and Methods:** We present three female cases, with different findings within the groin mimicking hernia.

**Results:** The first case regarding a Leiomyoma of the round ligament of the uterus, which are the most frequent tumors of the round ligament of the uterus, in the second case a 25year.old female with mesothelial cyst of the round ligament of the uterus as a palpable mass within the groin, and in the third a 42 year old female, with endometriosis in the groin also mimicking hernia.

**Conclusion:** Whilst hernia is a common finding in the groin the reason for it varies. A surgeon should be aware that in women in particular the findings could surprise them.

**Keywords:** Groin hernias, leiomyoma, mesothelial cyst, round ligament, endometriosis.

### Introduction

Groin hernias have a wide variety of clinical presentations, from a bulge in the groin recognized on a routine physical examination, to an emergency ileus, due to bowel obstruction and strangulation. Diagnosis rely mostly on the patient's history and/or clinical symptoms as well as on the physical examination. Advanced diagnostics such as computed tomography (CT) scan or magnetic resonance imaging (MRI) [1] are scarcely required.

There are cases when there is doubt in the

diagnosis, imaging can then help differentiate between inguinal hernia from other rare clinical entities [2, 3]. Ultrasound has been proven to help in the imaging diagnostics, which is noninvasive and inexpensive and has a high sensitivity and specificity [3]. CT or MRI scans can be helpful in cases of rare clinical conditions.

Masses within the groin region that can be: painful or not, soft tissue infection, lymphoid tissue, associated vessels or structures of the female reproduction system, and are a part of the differential diagnosis forming the bulge of inguinal hernia in a woman.

We present three female cases, with three different findings within the groin. In one case a 47-year-old (y.o) female with a leiomyoma of the round ligament of the uterus, which are the most frequent tumors

Address for correspondence and reprint requests to:  
Andreas Skarpas, Department Sismanoglion G.H Maroussi,  
Greece E.P.E. E-mail: andrewskarpas@gmail.com  
©2021 Skarpas D *et al.* Licensee Narain Publishers Pvt.  
Ltd. (NPPL)  
Submitted: Thursday, February 25, 2021 Accepted: Friday,  
March 19, 2021 Published: Friday, April 2, 2021

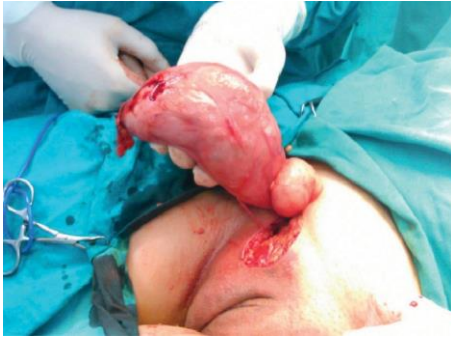

Figure 1 operative photograph showing content of hernia

of the round ligament of the uterus, in the other case, a 25 y.o female with mesothelial cyst of the round ligament of the uterus as a palpable mass within the groin, and in the last case a 42 y.o third female, with endometriosis in the groin, as a palpable mass within the groin.

**Case Presentation**

The first case, a 47y.o female patient without any significant medical history and a body mass index (BMI) of 26 kg/m<sup>2</sup> presented with a huge painless mass in the left inguinal region, complaining of sensation of pressure and discomfort in the area. Initially, an inguinal hernia was suspected; MRI was recommended, because of the bulge not subsiding with any maneuvers, and it revealed a soft tissue mass of 19 X 6 X 2.5 centimeters (cm), without any pathological lymph nodes. The patient underwent elective surgery under general anesthesia. A mass of the right roundligament of the uterus was

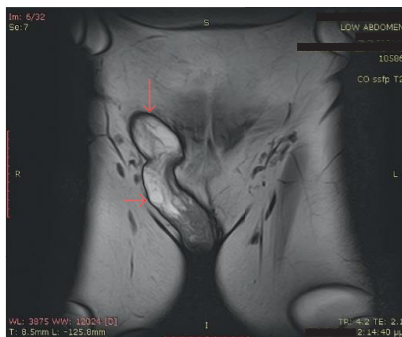


Figure 2: MRI image showing the hernial sac and content

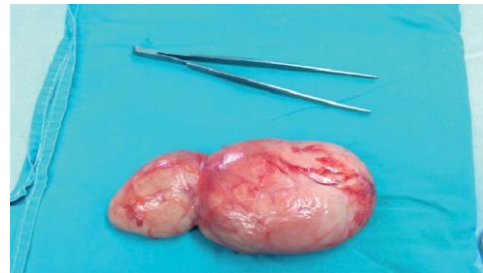

Figure 3: Postoperative picture of resected specimen

discovered with no concurrent hernia. The mass was completely excised. No complications were reported in the follow-up. Histopathological examination revealed a leiomyoma of the round ligament of the uterus (Figure 1-4).

The second case, a 25y.o female patient presenting with a palpable mass in her right inguinal region. The preoperative investigation through ultrasound (U/S), CT and MRI revealed the presence of an intraabdominal cystic lobular mass in the inguinal canal, in contact with the femoral vessels. The mass was excised, and the diagnosis of a benign mesothelial cyst was made through pathological examination. (Figure 5)

The third case a 42 y.o woman with a palpable mass within the right groin which led us to be an inguinal hernia. The patient had been complaining of pain for the last 3 years. Upon careful questioning the pain was more intense during her menstrual period. Though

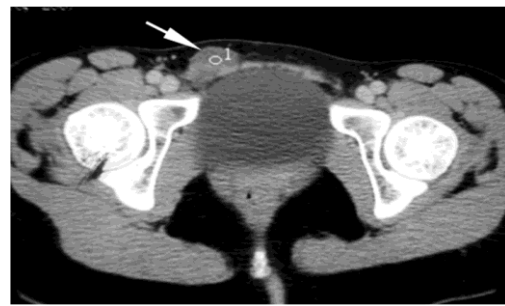


Figure 4: CT scan showing the globular cystic swelling in hernial sac

she underwent operation for a classical inguinal hernia, such was not found but rather tissue that after histological examination revealed, endometriosis, and such was the established diagnosis. (Figure 6)

## Discussion

The round ligament extends from the uterus, through the inguinal canal, and ends in the region of the mons pubis and labia major. Embryological, this is the female equivalent of gubernaculum testis and is predominantly composed of smooth muscle fibers, connective tissue, vessels, and nerves with a mesothelial coating [4].

Leiomyomas are the most frequent tumors of the round ligament of the uterus, followed by endometriosis and mesothelial cysts [5, 6]. In most cases, they present as inguinal masses in women of reproductive age. They can be mistaken for hernias or lymph nodes. Half to two-thirds of the cases regarding leiomyomas occur in the extra-peritoneal portion of the round ligament and are more common on the right side for unknown reasons.[5] The transformation of the myofibrous structure of the female genital tract to leiomyoma involves somatic mutations of normal smooth muscle and a complex interaction between sex steroids and local growth factors. Estrogen is the major promoter of the myoma growth. Except from inguinal locations, abdominal and vulvar locations have been reported[6, 7].

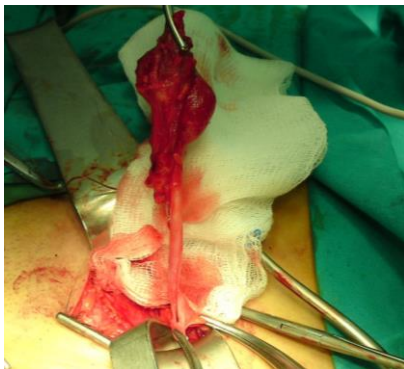


Figure 5: Operative photograph showing hernial sac

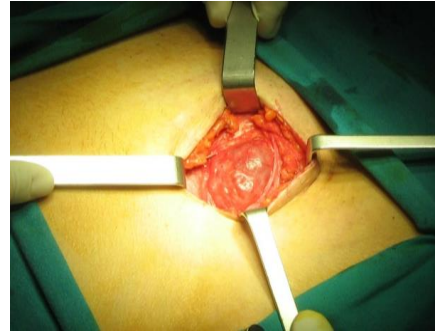


Figure 6: Operative photograph showing hernia

Examination of the specimen provides the final diagnosis.

There have been two theories suggested for the development of a mesothelial cyst of the round ligament. The first one is a flaw in the obliteration of Nuck's canal. In males, a comparable flaw in the obliteration may result in a cystic hydrocele. According to this theory, a round ligament cyst is the same disease as a cyst of the Nuck's canal. The other theory is the inclusion of embryonic mesenchymal mesothelial elements or remnants during the development of the round ligament [8] Cysts of mesothelial investment of the round ligament are lined with a single layer of flat, cuboidal cells that have the characteristic appearance of mesothelial cells. The round ligament cyst and Nuck's canal cyst ultimately show the same imaging and histologic features [9]

Endometriosis is an often painful disorder in which tissue that lines the uterus evolves outside the uterus. This affects about 10% of population, usually from the age of 25 to 45 y.o Endometriosis commonly involves the ovaries, fallopian tubes and the tissue lining the pelvis. It rarely, extends beyond the pelvic organs. Endometrial tissue thickens, and bleeds with each menstrual cycle. Because this has no way to leave, it becomes trapped. Surrounding tissue then becomes irritated, developing scar tissue and adhesions.

Surgical excision is the treatment of choice which could help the differentiate diagnosis between leiomyoma, inguinal lymphadenopathy, hernia, and a malignant tumor.

Imaging techniques before operation, such as computer assisted tomography (CAT) or MRI, can be helpful but are not always performed prior to surgery [10]. We don't usually send patients to CT Or MRI, but If a mass is suspected which comes with characteristics such as, hard consistency, not budging, abnormal movement, abnormal u/s finding, etc then we request extra imaging tests (CT, MRI).

### Conclusion

Groin hernias have a wide variety of clinical presentations. Masses that present as inguinal hernia vary. In women, Leiomyomas of the round ligament of the uterus, followed by endometriosis and mesothelial cyst, scan be but, are rare etiologies and can be mistaken for an inguinal hernia or lymphadenopathy and thus should be considered in the differential diagnosis of inguinal hernia. Extra imaging test as MRI and, if not possible, a CAT scan can assist when there is diagnostic dilemma. Eventually, surgical exploration provides therapy and defines the exact nature of the mass.

### Conflict of Interest

There authors declare that there are no conflicts of interest regarding the publication of this manuscript.

### Authors' Contribution

NN, IK, VG operated on cases and drafted the manuscript.

KP, AZ, GV, EG contributed in literature search and preparation of manuscript.

AS conceived and designed the study and edited the manuscript.

All authors read and approved the manuscript.

### Statement of Ethics and consent

Written informed consent for publication of these cases was obtained from the patients and is available with authors.

### Funding

None declared

### Acknowledgement

None

### References

1. Rosenberg J, Bisgaard T, Kehlet H, Wara P, Asmussen T, Juul P, et al. Danish Hernia Database recommendations for the management of inguinal and femoral hernia in adults. *Dan Med Bull* 2011; 58:C4243. [[PubMed](#)]
2. Robinson A, Light D, Kasim A, Nice C. A systematic review and meta-analysis of the role of radiology in the diagnosis of occult inguinal hernia. *Surg Endosc* 2013; 27:11–8. Doi: 10.1007/s00464-012-2412-3. [[PubMed](#)]
3. Bradley M, Morgan D, Pentlow B, Roe A. The groin hernia— an ultrasound diagnosis? *Ann R Coll Surg Engl* 2003; 85:178–80. doi:10.1308/003588403321661334 [[PubMed](#)] [[PMC Full Text](#)]
4. Warshauer DM, Mandel SR. Leiomyoma of the extraperitoneal round ligament: CT demonstration. *Clin Imaging*. 1999; 23:375–376. [[PubMed](#)]
5. David MW, Stanley RM. Leiomyoma of extraperitoneal round ligament: CT demonstration. *Clin Imaging* 1999; 23:375–6 [[PubMed](#)]
6. Vignali M, Bertulesi C, Spreafico C, Busacca M. A large symptomatic leiomyoma of the round ligament. *J Minim Invasive Gynecol* 2006; 13:375–6 [[PubMed](#)]
7. Fasih, A. K. Prasad Shanbhogue, D. B. Macdonald et al., "Leiomyomas beyond the uterus: unusual locations, rare manifestations," *Radiographics*, vol. 28, no. 7, pp. 1931–1948, 2008 [[PubMed](#)]

8. Harper GB Jr, Awbrey BJ, Thomas CG Jr, Askin FB. Mesothelial cysts of the round ligament simulating inguinal hernia. Report of four cases and a review of the literature. *Am JSurg* 1986;151:515-517 [[PubMed](#)]
9. Oh SN, Jung SE, Lee JM, Chung JH, Park GS. Sonographic diagnosis of a round ligament cyst in the inguinal area. *J Clin Ultrasound* 2007; 35:226-228 [[PubMed](#)]
10. J. Casillas, R. C. Joseph, and J. J. Guerra, "CT appearance of uterine leiomyomas," *Radiographics*, vol. 10, no. 6, pp. 999–1007, 1990. [[PubMed](#)]